



Low field MRI impact on interventions

Paul J.A. Borm, PhD, Orlando P. Simonetti, PhD and Aimee K. Armstrong, MD

Cathlab and MRI

While x-ray fluoroscopy continues to be the mainstay imaging method for cardiac catheterization procedures, it has numerous disadvantages, including poor soft tissue visualization, need for repeated injections of iodinated contrast to depict the anatomy, inability to visualize the anatomy during interventions, harmful effects of radiation, and the need for lead protection that can induce orthopedic injuries. The adverse effects of radiation are compounded in children, due to their greater mitotic activity. In addition, many congenital heart disease (CHD) patients need repeated cardiac catheterizations and radiation-based imaging throughout their lives, sometimes receiving accumulated lifetime doses that are associated with a detectable increased risk of cancer (1). Children also have longer lifespans than adults, thereby having more time to develop radiation-induced cancer.

Cardiac magnetic resonance (CMR) eliminates many of the disadvantages of x-ray, but it comes with its own challenges for real-time interventional imaging. The field of interventional CMR (ICMR) has been slow to advance, due to safety hazards from radiofrequency-induced heating of catheterization equipment during scanning, inability to visualize standard catheters with MRI, and large metallic artifacts from interventional wires that obstruct the imaging. The many drawbacks of x-ray imaging, however, continue to push clinicians, researchers, and industry to overcome these limitations in the field of ICMR.

Advantages and Needs

To date, the vast majority of ICMR work has been performed in 1.5 Tesla scanners. Clinical investigators at the National Institutes of Health (NIH) performed right heart catheterizations (RHC) in adults (2), and Ratnayaka and colleagues were the first to move ICMR into a pediatric hospital on a large scale, reporting 50/50 successful RHC procedures in children (3). As the field progressed, specific equipment was developed for catheterization to make wires and catheters safe and conspicuous in MRI. Nano4Imaging (Dusseldorf, Germany) has been a leader in this field and produced the first CE and FDA-approved guidewire (EmeryGlide MRWire) for ICMR by placing passive markers on the distal tip of fibre-polymer composite wire.

The composite material removes concerns for device heating and metal artifact, and the markers are visible under both MRI and x-ray fluoroscopy, allowing for use in both settings. This technology has helped to bring ICMR to the evaluation of patients with CHD, enabling procedures to measure pressure gradients across stenoses with real-time MR guidance (4) and assess hemodynamics during Fontan fenestration test occlusion (5). In addition to these procedures in CHD, diagnostic catheterization is routinely performed for pulmonary hypertension patients in many hospitals in the United Kingdom, France and Scandinavia. Procedure time has been shown to be equivalent to similar catheterizations with x-ray fluoroscopy, while radiation exposure is reduced to both patients and staff (6).

Current and future indications

While diagnostic catheterizations with MR guidance are being performed on a regular basis at some institutions, interventional procedures, such as angioplasty, stenting, and septal defect closures, are not part of clinical practice today, primarily due to the lack of equipment that is both visible and safe in the MR environment, the absence of supporting software, and uncertainty about reimbursement. An international survey of members of the pediatric interventional cardiology community at 175 centers in 2019 revealed that 14 centers have active ICMR programs, and physicians at 72 other centers are interested in starting a program. The major problems they envisaged or encountered were lack of a scanner in a location for safe ICMR procedures (26%), MR-safe medical devices (18%), physician training (13%), and training of key team members (12%). Hands-on training and workshops were mentioned as the prime needs to get started, while medical devices were also seen as important. The wish list of devices was topped by more MR conditional guidewires, followed by access kits, torque control catheters, angioplasty catheters, and a bioptome (7). The current and future clinical indications, which were outlined in 2019, are shown in Table 1; as it is now almost 5 years beyond the date of the survey, some of the "future" indications have been executed in animal and/or clinical studies.

Interested in reading the complete results of the interventional MRI work? Please read the paper *Why Low Field Imaging is Expected to Boost Interventional CMR Procedures* by the same authors in *Congenital Cardiology Today* (August issue 2023, Volume 21, issue 8).



ICMR TOP INDICATIONS IN 2019	PREDICTED ICMR TOP INDICATIONS IN 2023
Evaluation of pulmonary hypertension	Balloon angioplasty of branch pulmonary artery
Evaluation of post-heart transplant patients	Myocardial biopsy
Diagnostic evaluation of post-Fontan/single-ventricle patients	Fontan fenestration test occlusion and device closure
Pre-Fontan surgical evaluation	Balloon angioplasty of RV-PA conduit
Diagnostic right- or left-heart cath before shunt closure procedures	Balloon pulmonary valvuloplasty

Table 1. Current and future indications of ICMR, as indicated by 132 pediatric interventional cardiologists in a 2019 survey.

Groundwork

Early work in low-field (0.55T) MR scanners suggests that it has great potential to overcome some of the long-standing problems with ICMR. The lower field strength may allow the safe use of commercially available catheterization equipment. Campbell-Washburn et al. (8) showed that two types of nitinol non-exchange length guidewires and two types of stainless-steel braided catheters were safe at 0.55 T (<1°C heating) during 2 minutes of continuous scanning. They then performed low field MR-guided RHC successfully in 7/7 patients using a commercially available nitinol guidewire (180 cm 0.035" Micro J-tip Glidewire, Terumo, Tokyo, Japan) without complication or evidence of heating (8). These studies were performed on an investigational, modified commercial MRI system that operated at 0.55 T but retained the high gradient performance of the original 1.5T system (MAGNETOM Aera, Siemens Healthineers, Erlangen, Germany).

Low Field MRI available now

Since these studies were performed, a low field scanner has become commercially available (0.55T MAGNETOM Free.Max, Siemens Healthineers, Erlangen, Germany). The system has a wide, 80 cm bore diameter, facilitating patient access, but limited gradient performance (maximum gradient amplitude 26 mT/m, maximum slew rate 45 mT/m/ms). The system is more affordable than higher field, 1.5T and 3T scanners, as it is less expensive to manufacture, transport, and install and easier to operate. Most importantly for interventionalists, it may be the breakthrough that is needed to enable MR-guided interventional procedures, because of the decreased RF-induced heating that can allow the use of standard equipment, improved access to the patient in the wider bore, and multiple simpler safety and maintenance features. With FDA approval of the MAGNETOM Free.Max and multiple installations around the world, there is renewed energy in ICMR by clinicians and industry alike. The current platform still needs considerable development, such as imaging techniques and pulse sequences required for cardiovascular and interventional

imaging but is expected to make the difference for MRI-guided procedures in cardiology and interventional radiology.

Live case at PICS

Dr. Aimee K. Armstrong from Nationwide Children's Hospital (NCH) in Columbus, Ohio and a team at The Ohio State University (OSU) led by Dr. Orlando P. Simonetti, were the first to test the feasibility of performing right and left heart catheterization, inferior vena cava (IVC) angioplasty, and IVC stenting with real-time imaging in pre-clinical studies performed on the 0.55T MAGNETOM Free.Max (9). While many types of standard catheterization equipment can be used safely at low field, the devices must be made conspicuous, and this was accomplished by adding MagnaFy MR-visible markers (Nano4Imaging GmbH, Dusseldorf, Germany) to the standard equipment. Three different sizes of proprietary MagnaFy MR-visible markers were evaluated on Z-Med balloons (NuMED Inc., Hopkinton, NY). One of these cases was performed live during the Pediatric Interventional Cardiology Symposium (PICS) Chicago 2022 (Fig 1), and Fig 2 shows how a marked angioplasty catheter can be well distinguished in MRI from the ends of a crimped 26 mm long Mega LD stent (red arrows) to facilitate stenting of the IVC.

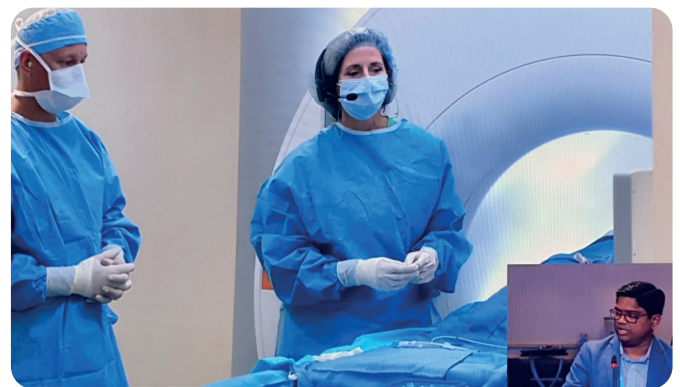


Figure 1. Dr. Aimee Armstrong (right) and Jason Swinning, RT(R)(CI), RCIS (left)(Nationwide Children's, Columbus, OH) during PICS 2022 live case stenting the IVC of a large animal with low field MRI guidance and being questioned by Dr. Suren Reddy (Dallas Children's- UT Southwestern).

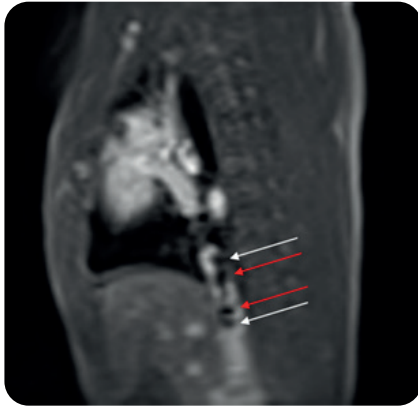

Figure 2: Low field (0.55 Tesla) CMR still frame showing MagnaFy® markers (white arrows) placed at the ends of the tapered tips of the 20 mm x 3 cm Z-Med balloon well distinguished from ends of crimped 26 mm long Mega LD stent (red arrows).

If low field MRI is going to be used clinically for ICMR in the future, further development and optimization of cardiac and interactive real-time imaging techniques is required to overcome the limitations of low signal-to-noise ratio and limited gradient performance. Fortunately, pre-clinical and clinical testing has already shown that a comprehensive CMR imaging protocol is feasible, including compressed-sensing 2D phase-contrast cine, dynamic contrast-enhanced imaging for myocardial perfusion, 3D MR angiography, and late gadolinium enhanced tissue characterization (10).

Open field lab in Ohio

In 2022, a dedicated collaboration was formed by clinicians at NCH, researchers at OSU, and multiple industry partners, and is already making positive steps towards bringing low-field MRI to the interventional space. In 2023, OSU continues to function as a field-laboratory for pre-clinical testing of devices and software from Siemens Healthineers, Nano4Imaging, Cook Medical, and NuMed. Together, these organizations continue to develop, optimize, and evaluate the hardware and software necessary to bring interventional procedures with real-time MR-guidance into routine clinical practice.

References:

1. Stern H, Seidenbusch M, Hapfelmeier A, Meierhofer C, Naumann S, Schmid I, Spix C, Ewert P. Increased Cancer Incidence Following up to 15 Years after Cardiac Catheterization in Infants under One Year between 1980 and 1998-A Single Center Observational Study. *J Clin Med*. 2020 Jan 22;9(2):315. doi: 10.3390/jcm9020315. PMID: 31979109
2. Rogers T, et al. CMR fluoroscopy right heart catheterization for cardiac output and pulmonary vascular resistance: results in 102 patients. *Journal of Cardiovascular Magnetic Resonance* 2017;19:54. PMID 28750642
3. Ratnayaka K, et al. Radiation-free CMR diagnostic heart catheterization in children. *J Cardiovasc Magn Reson*. 2017 Sep 6;19(1):65. PMID 28874164
4. Meierhofer C et al. Real-time CMR guidance for intra-cardiac and great vessel pressure mapping in patients with congenital heart disease using an MR conditional guidewire—results of 25 patients. *Cardiovasc Diagn Ther* 2021;11(6):1356-1366. PMID 35070804
5. Reddy SRV, Arar Y, Zahr RA, et al. Invasive cardiovascular magnetic resonance (iCMR) for diagnostic right and left heart catheterization using an MR-conditional guidewire and passive visualization in congenital heart disease. *J Cardiovasc Magn Reson* 2020 Mar 26;22(1):20. PMID 32213193
6. Knight DS, Kotecha T, Martinez-Naharro A, Brown JT, Bertelli M, Fontana M, Muthurangu V, Coghlan JG. Cardiovascular magnetic resonance-guided right heart catheterization in a conventional CMR environment - predictors of procedure success and duration in pulmonary artery hypertension. *J Cardiovasc Magn Reson*. 2019 Sep 9;21(1):57. PMID: 31495338; PMCID: PMC6732841.
7. Reddy S, Ewert P, Ratnayaka K, Halperin H, Gotto J, Hussain T, Greil G, Borm PJA. Current and future application of interventional CMR as alternative to the cathlab in congenital heart diseases. Results of an online survey. Poster presentation at PICS/AICS 2019, San Diego.
8. Campbell-Washburn A, Ramaswamy R, Restivo MC, et al. Opportunities in Interventional and Diagnostic Imaging by Using High-Performance Low-Field-Strength MRI. *Radiology* 2019 Nov;293(2):384-393. PMID 31573398
9. Armstrong A, Krishnamurthy R, Swinning J, Liu Y, Joseph M, Simonetti O. Feasibility of MRI-Guided Cardiac Catheterization, Angioplasty, and Stenting in a 0.55T Scanner with Limited Gradient Performance. PICS-AICS 2022, Chicago, IL, September 2022. Selected Abstracts from the PICS Society Symposium 2022 Marriott Chicago Downtown September 7–10, 2022. *Pediatr Cardiol* 43, 1934–2029 (2022). <https://doi.org/10.1007/s00246-022-02969-y>
10. Varghese J, Jin N, Giese D, et al. Building a comprehensive cardiovascular magnetic resonance exam on a commercial 0.55T system: A pictorial essay on potential applications. *Frontiers in Cardiovascular Medicine* 01 March 2023. doi: 10.3389/fcvm.2023.1120982